



**PATIENT**

Teddy Binder

**SPECIES**

Canine

**BREED**

Shih Tzu

**SEX**

Male Intact

**AGE**

13 years

**WEIGHT**

17.54lbs

**INTERPRETED BY**

Maggie Machen  
 Lamy, DVM, DACVIM  
 (Cardiology)

**IMAGING PERFORMED BY**

Jenna Walsh, CVT

**HOSPITAL NAME**

Morgan Veterinary  
 Hospital

**REFERRING VET**

Dr. Jernstedt

**INVOICE**

23499

**DATE**

4/6/22

**PRESENTING CLINICAL SIGNS**

History: Coughing. Heart murmur. Resting RR: 36, BP: 108mmHg.  
 -Current medications: Lisinopril 10mg: 1/2 tab PO BID, Furosemide 12.5mg: 1 tab PO BID, Vetmedin 5mg: 1 tab PO SID.

**RADIOGRAPHIC FINDINGS** \*NOTE: Images submitted for supplemental cardiac information only.  
 A single lateral film is included. Mild cardiomegaly. No obvious evidence of CHF.

**ELECTROCARDIOGRAPHIC FINDINGS** \*Note: Single lead ECGs are evaluated as a rhythm strip. Morphology/MEA cannot be definitively commented on.  
 A single lead ECG is available; 50mm/s, 20mm/mV. The average heart rate is 180bpm (range 166-220bpm). The rhythm is sinus in origin, with a p for every QRS complex and vice versa. The P and QRS morphologies are positive. No ectopic beats, pauses or dysrhythmias observed.  
 ECG diagnosis: Normal sinus tachycardia.

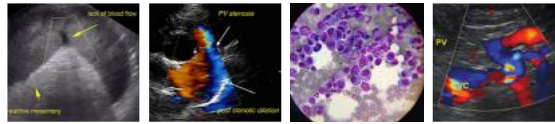
**ECHOCARDIOGRAM FINDINGS**

2D, m-mode, color flow and doppler imaging is available. Diffuse thickening of mitral valve leaflets (anterior>posterior) with mild prolapse into the left atrial lumen. Moderate eccentric mitral regurgitation with moderate left atrial dilation. Normal MR velocity. Mildly increased LV diameter with hyperdynamic myocardial function. The tricuspid valve appears subjectively normal, with trace tricuspid regurgitation. Velocity consistent with early pulmonary hypertension. Normal right atrial and ventricular diameter. The pulmonic and aortic valves are normal in morphology and mobility. Normal pulmonic and aortic outflow velocities. No aortic or pulmonic insufficiency. No pericardial or pleural effusion noted. No cardiac tumors observed.

**CARDIAC CHART**

CANINE CARDIAC PARAMETERS	MR VMAX (m/s)	TR VMAX (m/s)	LA/AO (Boon method)	LA/AO (Heart Base; Swe)	FS (%)	EF (%)	EPSS (cm)
NORMAL PARAMETER	4.5-5.5	<2.7	1.3	<1.6	28-40	40-100	<0.6
PATIENT	6.2	3.0	1.3	1.6	39	70	0.3
CANINE CARDIAC PARAMETERS	HR (BPM)	AV VMAX (m/s)	PV MAX (m/s)	BODY WEIGHT (kg)	LA 2D short axis Base view (cm)	LVIDd Avg; 2D and m-mode short axis (cm)	LVIDs Avg; 2D and m-mode short axis (cm)
NORMAL PARAMETER	50-100	0.7-1.7	0.7-1.6	BELOW	BELOW	BELOW	BELOW
PATIENT	120	0.9	0.8	8.0	2.5	3.2	1.9
*Normal chamber parameters expressed as a mean value (SD)				3	1.27 (5.3)	2.46 (2.46)	1.36 (5.5)
<b>BODY WEIGHT DEPENDENT PARAMETERS</b>				5	1.40 (4.5)	2.74 (5.2)	1.60 (4.7)
				10	1.50 (3.8)	3.27 (3.5)	2.06 (3.1)
				15	1.83 (2.0)	3.71 (2.4)	2.43 (2.1)
				20	2.02 (1.9)	4.14 (2.2)	2.80 (2.0)
				25	2.18 (2.4)	4.48 (2.9)	3.10 (2.5)

Adapted from June Boon, Veterinary Echocardiography, 1998  
 Rishniw M and Hollis NE, J Vet Intern Med 2000; 14:429-435  
 Hansson et al, Vet Rad and Ultrasound 2002



## PATIENT

Teddy Binder

Bonagura et al. Echocardiography: principles of interpretation, Vet Clin North Am 15:1177, 1995	30	2.33 (3.3)	4.83 (3.9)	3.39 (3.4)
	35	2.48 (4.3)	5.17 (5.0)	3.69 (4.5)
	40	2.62 (5.2)	5.48 (6.1)	3.96 (5.4)
	50	2.88 (7.1)	6.07 (8.3)	4.46 (7.4)

## SPECIES

Canine

## BREED

Shih Tzu

## SEX

Male Intact

## AGE

13 years

## WEIGHT

17.54lbs

## INTERPRETED BY

Maggie Machen  
Lamy, DVM, DACVIM  
(Cardiology)

## IMAGING PERFORMED BY

Jenna Walsh, CVT

## HOSPITAL NAME

Morgan Veterinary  
Hospital

## REFERRING VET

Dr. Jernstedt

## INVOICE

23499

## DATE

4/6/22

## INTERPRETATION OF THE FINDINGS & FURTHER RECOMMENDATIONS

Chronic degenerative valve disease causing moderate mitral and trace tricuspid regurgitation. Moderate left atrial enlargement indicates there is relatively low risk for imminent complication, however risk for progression to spontaneous congestive heart failure in the future is elevated. Early pulmonary hypertension is noted, which is likely secondary to a reported cough. No additional issues are identified. The ECG is unremarkable with a normal sinus tachycardia.

Given these findings, continue Pimobendan is indicated in this patient as below at BID dosing. Assessment of progression in the future will help predict long term outcome, however prognosis is guarded at this stage (B2).

While mainstem bronchi compression may certainly be contributing to a chronic increase in coughing, other primary airway contributions should also be considered (tracheal collapse, COPD/chronic bronchitis, etc.). Consider hydrocodone for any mechanical component due to cardiomegaly. **Assuming the included chest radiograph is current, this would suggest noncardiac causes for the cough is more likely and Lasix can be safely discontinued. Additionally, the patient is relatively hypotensive, and Lisinopril should also be discontinued.** If there is any question on the diagnosis, repeat films with a Radiologist review is strongly recommended.

Omega fatty acid supplementation and mild salt restriction may also be of some long-term benefit. Monitor for development of a progressive cough, labored breathing, exercise intolerance or collapse episodes.

Anesthetic risk is considered mildly elevated. Cardiac protective drug choices (opioid/benzodiazepine premedication, Propofol or alfaxalone induction, iso or sevo gas) are recommended. Monitor for arrhythmias, hypotension, and hypoxia both intra and post-operatively and intervene as necessary. Judicious IV fluid rates are recommended to avoid fluid overload. Avoid heart rate stimulating drugs such as atropine unless clinically indicated.

## PLAN

Administer Pimobendan 0.3mg/kg PO **q12h**. Consider hydrocodone as discussed. If needed repeat CXR with a Radiologist review; otherwise discontinue Lasix and ACE-I as discussed.

Recommend monitor for progression with a recheck echocardiogram in 6 months, sooner if any development of clinical signs.



**PATIENT**

Teddy Binder

**SPECIES**

Canine

**BREED**

Shih Tzu

**SEX**

Male Intact

**AGE**

13 years

**WEIGHT**

17.54lbs

**INTERPRETED BY**

Maggie Machen Lamy, DVM, DACVIM (Cardiology)

**IMAGING PERFORMED BY**

Jenna Walsh, CVT

**HOSPITAL NAME**

Morgan Veterinary Hospital

**REFERRING VET**

Dr. Jernstedt

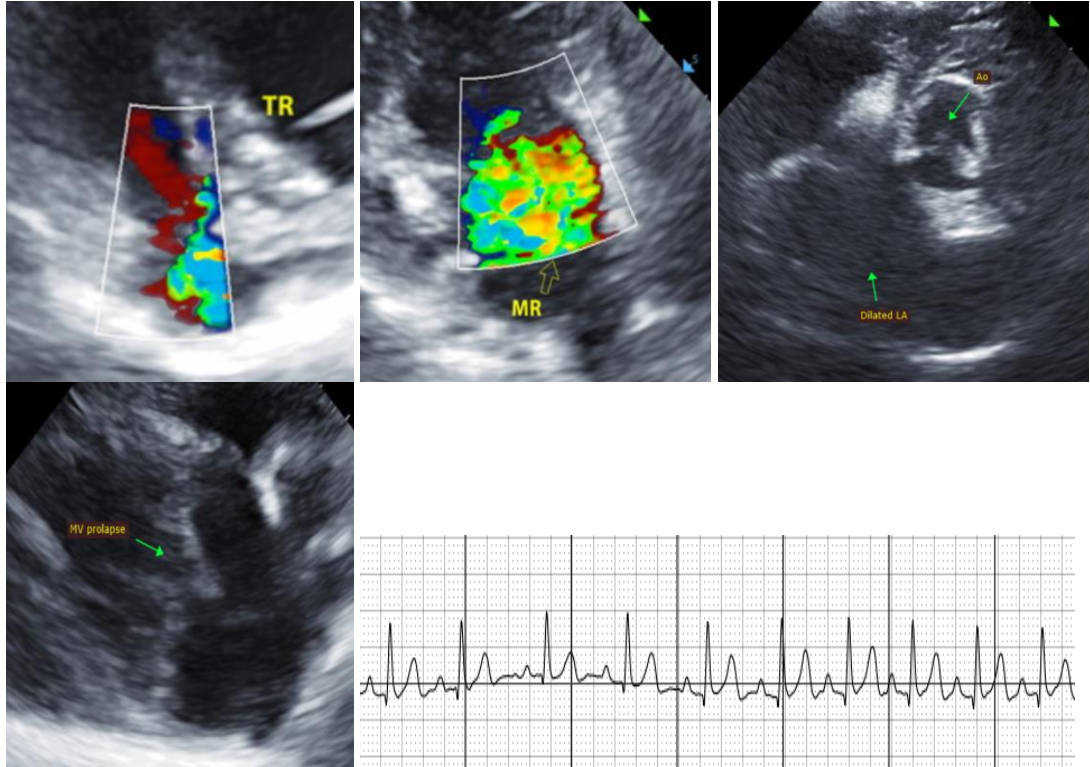
**INVOICE**

23499

**DATE**

4/6/22

**IMAGES**



The information and recommendations provided are based on the images presented by the referring veterinarian. No evaluation can be communicated regarding pathology that was not visible in the image/video clips provided.

Thank you for this referral. This report was generated using transcription software, and minor dictation errors may be present. If the clinical or image interpretation does not parallel your findings or if I can be of any further assistance, please contact me.

**Maggie Machen Lamy, DVM**  
 Diplomate of the American College of Veterinary Internal Medicine (Cardiology)  
 info@sonopath.com